

TRANSFORMATIONAL LUMBAR INTERBODY FUSION FOR TREATMENT OF LOW GRADE LUMBAR SPONDYLOLYTHESIS WITH STENOSIS

Mamdouh Mohammed Alkaramany and Waleed Mohamed Fathimoussa
Orthopaedic Department, Faculty of Medicine, Benha University, Benha, Egypt

ABSTRACT

Study design: prospective study. **Objectives:** evaluation of Transformational lumbar interbody fusion (TLIF) technique for symptomatic degenerative lumbar spondylolysis with stenosis. **Background:** there are many options for treatment of lumbar spondylolysis. Anterior fusion techniques are considered the most effective options theoretically and practically in comparison to the posterior fusion. TLIF through unilateral approach can attack both problems by the same approach via foraminal decompression and through the decompressed area any graft material can be applied. **Purpose:** to develop stable, painless spine and to avoid complications and limitations of other fusion techniques. **Patients and methods:** 25 female patients with mean age of 47 years (range 41-52) were included. Spondylolysis affect L4-L5 in 17 patients and L5-S1 in 8 patients. All patients had radicular and mechanical symptoms. All were treated with TLIF and fixed with Pedicular fixation. **Results:** Evaluation of the results was done through functional and radiologic assessment for an average of 40 months, 72% of patient had minimal disability, 16% moderate disability and 12% severe disability. **Conclusion:** TLIF is a reliable, effective techniques that allows a three-column fusion through a single approach in comparison to the less effective posterolateral fusion and more demanding anterior approach.

Correspondence to: Mamdouh Mohammed AL Karamany, MD, Ass. Professor orthopedic surgery. Orthopedic department, Benha University El-Shaheed Farid Nada Street, Benha, Qalyubia, Egypt, Tel: 01227323479;

E-mail: mhmedsharaf@yahoo.com

INTRODUCTION

Patients with symptomatic degenerative or ischemic lumbar spondylolysis may suffer from pain either mechanical and or radicular with functional disability. Studies showed that spinal fusion resulted in improved clinical results in cases with failed conservative treatment (1).

Through transformational lumbar interbody fusion (TLIF), fusion could be achieved in a circumferential fusion with a single approach. Stability can be achieved through pedicle screw fixation. With the same procedure, central, lateral recess or foraminal decompression can be done via pars interarticularis excision and inferior facetectomy which allows good visualization and nearly without retraction of the nerve root (2).

TLIF is indicated in any spinal disorders which may need fusion and decompression such as post laminectomy syndrome, discogenic low back pain, degenerative lumbar scoliosis or stenosis and correction of kyphosis with failure of non-operative treatment (3, 4).

PATIENTS AND METHODS

This work was conducted in Benha university hospital and Al-helal hospital between January 2011 and June 2013.

The study included 25 patients, all were females. The mean age was 47 years (range 41-52). Seventeen patients had L4-L5 spondylolysis and eight patients had L5-S1 spondylolysis. The degree of slippage was grade 1 in 15 patients and grade 2 in 10 patients. The presenting symptoms were low back pain, catching in all patients and 17 of them had neurologic claudication.

The surgical indications in all patients were persistence of symptoms and signs of instability after conservative treatment of at least 6 months, in addition to radiologic picture of the instability. Associated spinal stenosis was another indication of surgery.

All patients were treated with TLIF through the affected site and a banana cage was introduced through the same site and the affected segment was fixed with pedicular screws and rods.

Preoperative evaluation:

Clinical evaluation:

All patients were evaluated pre-operatively and at follow-up by reporting their pain using a visual analogue score (VAS) composing of 11 points where 0 no pain and 10 is maximum pain. All patients completed Oswestry disability index (ODI) score. This

scoring system is composed of 10 sections, including pain, personal care, lifting, walking, and activities of daily living. Every section of the score includes 5 grades starting from the normal to the worst functional condition (5).

Radiologic evaluation:

Plain x ray views were done for all patients, oblique stress view and Knutson's views in the form of flexion in standing position and extension in sitting positions.

MRI was done for all patients to diagnose associated disc prolapse, foraminal stenosis, and soft tissue compressing the roots or adjacent degenerative disc disease.

The operative technique of TLIF:

- Anesthesia: general hypotensive anesthesia.
- Position: prone, abdomen hanging free on radiolucent spinal frame.
- Local preparations: sterilize and draping.
- Infiltration of skin and deep tissues with adrenaline in saline.
- Midline posterior incision.
- Deep dissection down to lamina and facet joints.
- The exact level is confirmed by fluoroscopy.
- Decompression of the isthmic spondylolysis by Gill procedure (spinous process, lamina, inferior articular process) and the attached ligamentum flavum.
- Removal of superior articular process of the caudal level.
- Retraction of cranial (exiting) nerve root and caudal nerve root.
- Temporary fixation of Pedicular screws
- Entering the intervertebral disc space through an incision of the posterior longitudinal ligament and anulotomy and sometimes with excision of osteophytes and the bony lip of the superior end plate.
- Debridement of the intervertebral disc (IVD) by curette or sometimes with special box osteotome to create a bed for the cage. Placement of the banana cage through a unilateral TLIF in the anterior 2/3 of the IVD after filling the cage with bone chips.
- Removal of the pedicular distractor.
- Tightening of nut, over the rod and the pedicular screw.

- For more secure fusion, a posterolateral bone graft can be put.
- Closure of the wound over a drain.

Patients were followed in the clinic after 2 weeks for stitch removal and every 4 weeks for clinical and radiographic examination for 1 year, then every 6 months. Postoperative brace was used for six weeks and immediate weight bearing was allowed as tolerated. Patients were instructed to avoid heavy lifting for at least 6 months, and allowed to return to their work after 6 weeks. Patients were scored using VAS for pain and ODI scores.

RESULTS

The average duration of follow up was 40.4 months (range 36 to 45). At final follow-up, the average preoperative VAS for pain improved significantly from 5.6 (range 4 -7) to 2.1 (average 1-3) ($p < 0.001$). Similarly, average ODI score improved from 20.5 (range 16-36) to 9.3 (range 4-22) ($p < 0.0001$). According to ODI at final follow up 72% of patients showed minimal disability, 16% moderate disability and 12% severe disability.

Radiologically, interbody fusion could be achieved in 88% of the cases. No cases of implant failure were detected.

Complications:

Dural tear occurred in three patients (12%). Nerve root affection was recorded in 16% of patients which was transient and improved after an average of 4 weeks. Deep infection occurred in two patients (8%) which was patient managed by debridement and antibiotic treatment. Malposition of the cage occurred in two patients one has neurologic deficit and the other was asymptomatic. Three patients had nonunion (12%), one was asymptomatic and two patients were symptomatic who were treated after one year by revision of the fusion.

CASE PRESENTATION

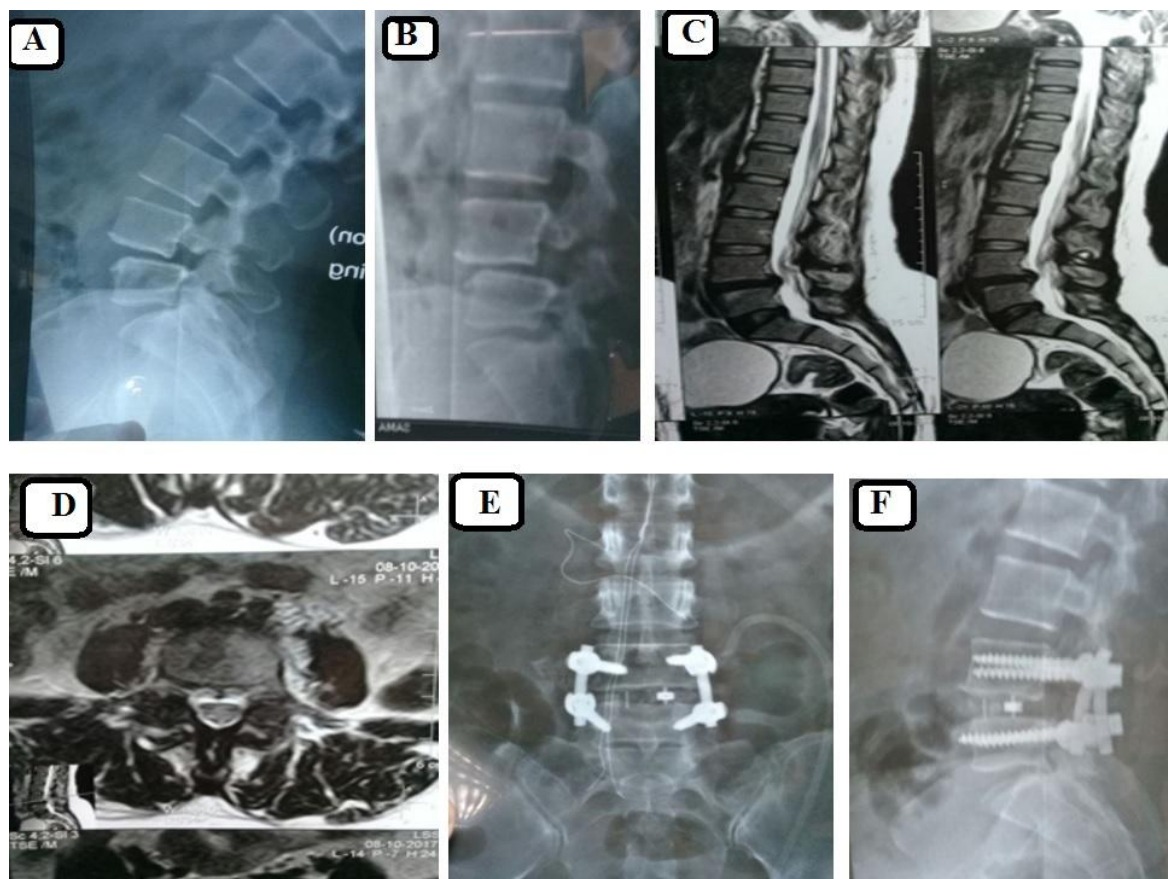
Female patient 43 years' house wife with low back pain and right lower limb parasthesia, tingling and numbness 3 years ago increased with walking sometimes increased at night when patient was lying on the affected side with failed conservative treatment in the form of physiotherapy and 1 epidural injection of corticosteroids.

Clinically patient had positive impulse on cough, positive straight leg rising at 60 degrees, parasthesia and numbness with non-dermatomal

distribution. Preoperative VAS was 5 and ODI was 20. Radiologically Patient had L4/5 spondylolithesis grade 1 and L4/5 disc prolapse with foraminal stenosis (fig.1).

Patient was operated upon in June 2013, and TLIF was done with fixation by 4 pedicular

screws and rods and banana cage. Fusion was achieved by 4 months and postoperative VAS for pain at last follow up was 1 and ODI was 6. Patient was very satisfied and returned to her previous activity level.



A: lateral radiograph showing L4/L5 grade 1 spondylolithesis, B: lateral radiograph extension view, C: MRI L4/L5 disc of low signal intensity, D: MRI L4,L5 disc extrusion and foraminal compromise, E :L4,L5 pedicular fixation with banana cage .AP view, F : L4,L5 fixation ,distracted disc space and

DISCUSSION

TLIF has a successful rate of fusion ranging from 90 – 100% with posterior fixation however; inadequate mortise construction and bone graft fitting are perhaps the most common preventable error leading to failure and complications. (3)

Interbody cage adds to the advantages of TLIF and avoid its disadvantages such as graft retropulsion, settling or late collapse.(6) Banana-shape interbody cage has the privilege of being unilaterally applied with minimal complication to the neural tissue especially the nerve roots and allows 75% coverage of intervertebral disc space.(7) Radiolucency permits a precise follow-up of a bony fusion and a metal marker provides the exact location on the x –ray pictures. Finally, it has an elastic modulus close to that of bone, so the graft is under optimal fusion conditions. (8)

Adding posterolateral fusion to the interbody cage in the TLIF improves the fusion

rate through fusion of the three columns of the motion segment which is called circumferential or global fusion through one posterior without another anterior approach. The circumferential fusion represents the most reliable strategy in achieving fusion 92 %in comparison to posterolateral fusion alone (82%) and restoration of the sagittal lordosis with improved long-term functional outcome when compared with other technique. Additionally, the reoperation rate is lower with the circumferential fusion (7%) as compared with posterolateral fusion (22%). (9)

In the current study a fusion rate reached 88% 25 female patients managed with TLIF. The average postoperative pain VAS was 2.1. According to ODI at final follow up 72% of patients showed minimal disability, 16% moderate disability and 12% severe disability. Such results match results obtained in similar studies (table1).

Table 1 showing results in different series using TLIF

Studies	Year	Number of patients	Mean age(range)	Mean followup in months	Fusion rates	Results
Potter et al (10)	2005	100	38(18-72)	34(24-61)	93	In 81% more than 50% reduction in symptoms and 70% satisfied 20% moior complications
Hackenberg et al (11)	2005	52	98.6(19-69)	46(36 -64)	89	Significant reduction in ODI score 8% complications
Lauber et al (12)	2006	39	48.1(17-80)	35.4 (24-78)	94.8	Significant improvement in pain and functional score 7.6% serious complications.
Our study	2015	25	47(41-52)	40.4(36-45)	88	74% very good 16% fair 10% poor.

Potter et al, found that TLIF is an effective method of achieving lumbar fusion with 93% of patients has 50% decrease in symptoms and only 29% were entirely pain free. Complications from the procedure were found to be uncommon and generally transient. (10)

Hackenberg et al, found that TLIF in 52 patients resulted in 89% fusion rate. Significant improvement in pain was demonstrated using ODI. (11)Lauber et al. reported 94% fusion rate, and only 7.6% complication rates. (12)

The decompression procedures prior to TLIF avoid retraction of the exiting nerve root and durra and facilitate the insertion of a unilateral cage with minimal complications compared to PLIF. (13, 14)

CONCLUSIONS

The TLIF has the advantages of performing interbody fusion with or without posterolateral fusion through the same posterior approach. The more lateral approach avoids retraction of neural tissue, durra and nerve root. The fusion rate of PLIF and TLIF is the same, but TLIF is more safe than other techniques of interbody fusion.

REFERENCES

1. **Moller H, Hedlund R.** Surgery versus conservative management in adult isthmic spondylolisthesis: A prospective randomized study. Part I. *Spine*.2000; 25:1711–1715.
2. **Madan S, Boeree NR.** Outcome of posterior lumbar interbody fusion versus posterolateral fusion for spondylolytic spondylolisthesis. *Spine*.2002; 27:1526–1542.
3. **Abdu WA, Lurie JD, Spratt KF.** Degenerative spondylolisthesis: does fusion method influence outcome? Four-year results of the spine patient outcomes research trial. *Spine*.2009;34(21) :2351-2360.
4. **Adogwa O, Parker SI, Davis BJ.** Cost effectiveness of transforaminal lumbar interbody fusion for grade 1 degenerative spondylolythesis. *J neurosurgery spine*.2011; 15(2):138-143.
5. **Fairbank JC, Pynsent PB.** The Oswestry Disability Index. *Spine*. 2000; 25(22):2940-2952.
6. **Gill GG, Manning JG, White HI.** Surgical treatment of spondylolythesis without spine fusion: excision of the loose lamina with decompression of the nerve roots. *J bone joint surg*. 1955; 37A (3):493-520.
7. **Harms J, Jeszenszky D.** The unilateral transforaminal approach for posterior lumbar interbody fusion *orthoptraumatol* 2: 88-89, 1998.
8. **Javernick MA, Kuklo TR, Polly DW.** Transforaminal lumbar interbody fusion: Unilateral versus bilateral removal-an invivo study. *Am j orthop*.2003; 32(7): 344-348.
9. **Kwon BK, Berta S, Daffner SD.** Radiographic analysis of transforaminal lumbar interbody fusion for the treatment of adult isthmic spondylolythesis. *J Spinal Disorder Tech*. 2003; 16(5): 469-476.
10. **Potter BK, Freedmen BA, Verwieble EG, Hall JM, Polly DW.** Transforaminal lumbar interbody fusion: clinical and radiographic results and complications in 100 consecutive patients. *J Spinal Disord Tech*. 2005; 18(4): 337-346.
11. **Hackenberg I, Halm H, Bullmann V, Vieth V, Schneider M, Tiljenquist U.** Transforaminal lumbar interbody fusion: a safe technique with satisfactory three to five years results. *Eur Spine J*. 2005; 14(6): 551-558.
12. **Lauber S, Schulte TL, Lilienqvist U, Halm H, Hackenberg I.** Clinical and radiologic 2-4 year results of transforaminal lumbar interbody fusion in degenerative and isthmic spondylolythesis grades 1 and 2. *Spine*. 2006; 31(15): 1693-1698.
13. **Yan DI, Pei FX, Lij AL.** Comparative study of PLIF and TLIF treatment in adult degenerative spondylolythesis. *Eur Spine J*. 2008; 17 (10): 1311-1316.
14. **Woods RU, Baron EM, Anand N, Vaccaro AR.** Transforaminal interbody fusion. In : *spine surgery operative techniques*, 2nd ed. Elsevier, Saunders, 2012, P305-313.